

Case report

**CONGENITAL PSEUDARTHROSIS OF THE ULNA AND
THE COMBINED TREATMENT TO RESTORE FOREARM
LENGTH AND CREATE A ONE-BONE FOREARM:
A CASE REPORT**

**Yuddhasert Sirirungruangsarn, M.D., Anupong Laohapoonrungrsee, M.D.,
Kanit Sananpanich, M.D.**

Department of Orthopaedics, Faculty of Medicine, Chiang Mai University

Abstract Isolated congenital pseudarthrosis of the ulna is a rare condition. The cause of pseudarthrosis remains controversial. Treatment of this condition is challenging and difficult. The aims are stabilizing the extremity, preventing shortening and deformities, and improving hand function. We report a case of isolated congenital pseudarthrosis of the ulna with a dislocated radial head. The patient had an unstable elbow with a short-bowed forearm. Ilizarov external fixator was applied to pull the proximal radius downward to restore forearm length prior to creation of a one-bone forearm. At two years follow up, the patient had a good hand function and stable elbow with forearms of equal length. Our technique is a successful option in the treatment of congenital pseudarthrosis of the ulna with a large bony defect and a dislocated radial head. **Chiang Mai Med Bull 2006;45(3):133-138.**

Keywords: Congenital pseudarthrosis, ulna, one-bone forearm

Isolated congenital pseudarthrosis of the ulna is rare. Only 37 cases have been described in the English literature.⁽¹⁻²⁰⁾ Although the occurrence of pseudarthrosis associated with neurofibromatosis is well documented, the cause of pseudarthrosis remains controversial^(1,2,3). If untreated, this condition leads to progressive forearm deformity, due to continued radial growth in the presence of an ulnar tether. The end result is a short-bowed forearm with a dislocated radial head. The

multiplicity of treatment methods, which have been described for this condition, is a reflection of the difficulty in obtaining bony union. These have included cast immobilization, non-vascularized bone grafting with and without internal fixation, creation of a one-bone forearm, free vascularized fibular grafting, and the Ilizarov compression-distraction technique. No single procedure has been seen as better than the others because of the rarity and varied severity of this condition. We report a case of

isolated congenital pseudarthrosis of the ulna with a dislocated radial head, which was treated by gradual distraction proximal radius distally, with Ilizarov fixator prior to the creation of a one-bone forearm.

Case Report

A boy was first seen at the age of 4 years with a deformity of the right forearm. He was treated by plastic forearm splint to prevent progressive deformity and became lost to follow up. He returned to the hospital again when he was 9 years old with excessive radial bowing of the right forearm, and marked prominence over the lateral aspect of the elbow (Fig 1.), and he complained of pain in the forearm on exertion. The length of the right forearm was 5 centimetres shorter than his left one. Elbow flexion was 140°, with 10° hyperexten-

sion. Pronation was limited by 10°, supination was full, and the hand functioned normally. He could not lift objects heavier than 5 kilograms with the right forearm. He had multiple cafe-au-lait spots all over the body, and Lisch's nodules in both eyes. Radiological examination showed a tapered sclerotic of the proximal ulna, and absence of middle and distal ulna. The normal bow of the radius was exaggerated and its head was dislocated anterolaterally and proximally. There was medial instability on a valgus stress test of the elbow of 30° flexion.

The Ilizarov external fixation was applied to pull the proximal radius downward by 1 mm/day (Fig 2.). Two months later the patient underwent a "one-bone forearm" operation. The head and neck of the radius proximal to biceps brachii insertion, and also the dysplastic ulna segment at the same level, were resected.

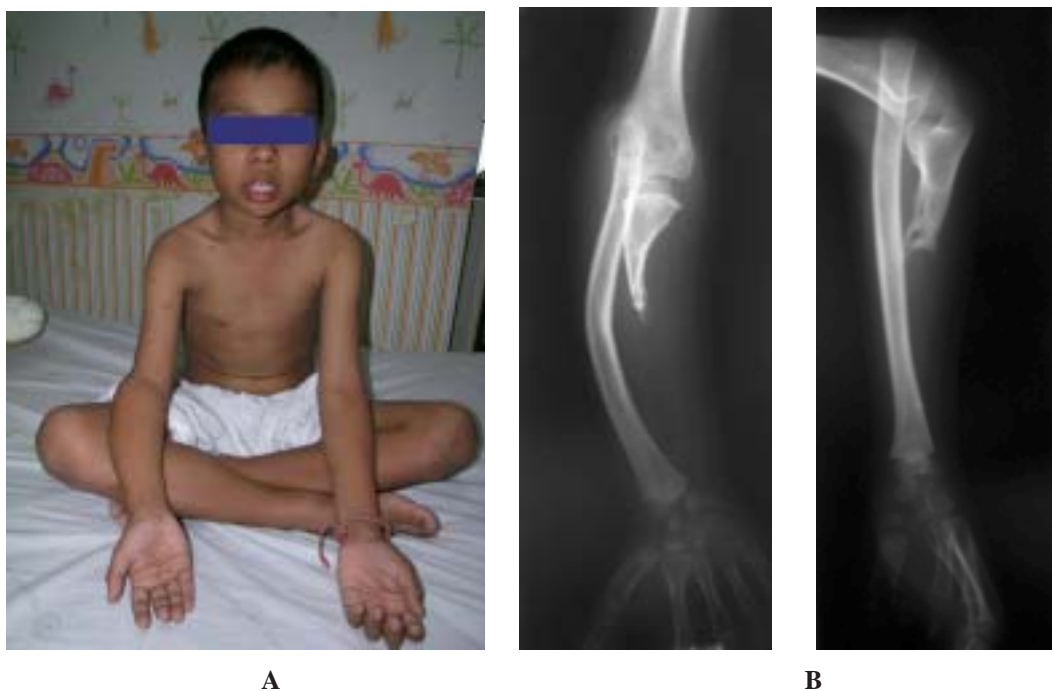


Figure 1. Clinical photograph (A) showing a short-bowed right forearm and marked prominence over the lateral aspect of the elbow, and anteroposterior and lateral x-ray films (B) showing congenital pseudarthrosis of the ulna with radial head dislocation.

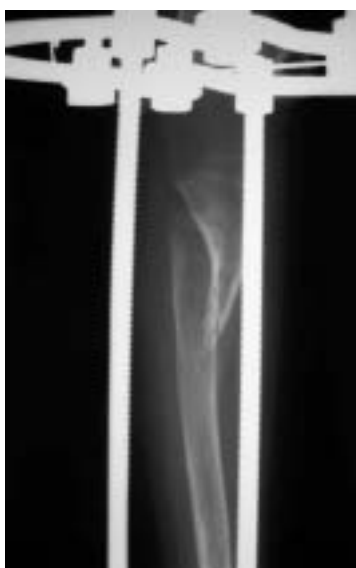

Figure 2. The position of the proximal radius 2 months after gradual distraction with Ilizarov fixator.

Also, the proximal ulna was apposed to the distal radial segment, and these bones were fixed with an intramedullary pin and 1/3 tubular plate. Autogenous cancellous bone grafts from the iliac crest were placed around the junction. Histologic examination of the resected bone and soft tissue showed reactive bone, hyaline cartilage, and dense fibroconnective tissue consistent with a congenital pseudarthrosis. A long arm cast was worn postoperatively for 6 weeks and exercise started after removal. The radiographs showed complete union at 8 weeks after surgery (Fig 3.). The intramedullary rod and plate were removed 8 months after fixation (Fig 4.). At two years follow up, the patient had good hand function with forearms of equal length, and he could lift objects heavier than 7 kilograms. Elbow power of the right forearm was comparable with the left one and there was a full range of flexion and extension motion. Pronation was limited by 10° and supination was 30°. Elbow function was stable and pain-free (Fig 5.)

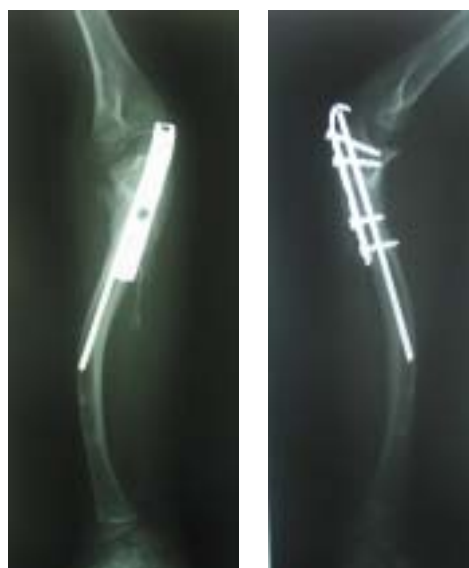

Figure 3. Eight weeks after Ilizarov fixator removal and internal fixation with a plate, screws, intramedullary pin and iliac bone graft to create a one-bone

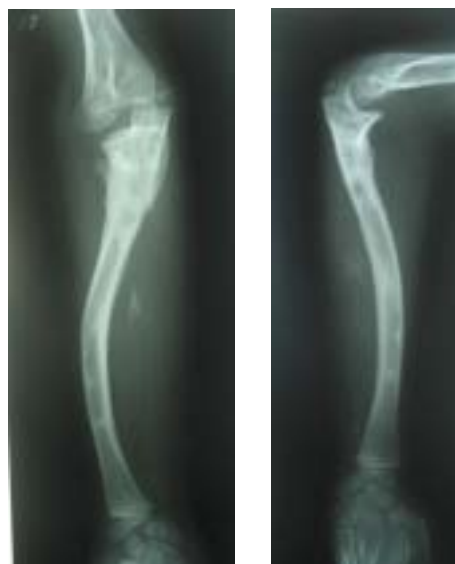

Figure 4. Final radiographs after implants removal, showing a one bone forearm.

Discussion

Congenital pseudarthrosis of the ulna is a rare condition. It is closely association with

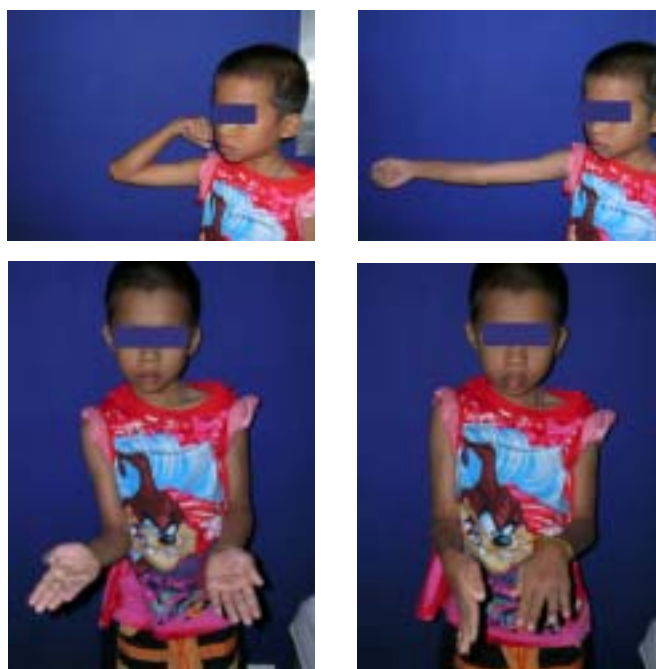

Figure 5. Final examination 24 months after the one-bone forearm operation showing the patient with a stable and pain free elbow and forearm of equal length. He had full range of flexion and extension motion of the right elbow with limited forearm rotation.

neurofibromatosis, which was reviewed by Witoonchart in 1999.⁽¹⁷⁾ He reported that 73% of cases had signs or positive family history. Treatment of congenital pseudarthrosis of the ulna is challenging and difficult. The aims are stabilizing the extremity, preventing shortening and deformities, and improving hand function. In most cases, brace or cast immobilization alone is likely to fail in producing union, especially in patients with neurofibromatosis.^(1,2,6,10) Several investigators have reported successful attempts with various surgical procedures. Treatment decision must take into account the patient's age, number of previous surgeries, amount of bony defect, availability of distal ulnar epiphysis, stability of the elbow, and surgical expertise. Non vascularized bone grafting with or without internal fixation is an option, but inappropriate for patients with a large bone gap.^(6,7,10)

The Ilizarov compression-distraction technique has been used commonly in the treatment of congenital pseudarthrosis of the tibia.⁽²¹⁾ It was reported in treatment of congenital pseudarthrosis of the ulna by Fabry *et al*, in 1988.⁽⁹⁾ This technique was successful in a case with a short bony defect, and not an option in a case such as ours, in which the greater part of the ulna was absent. Free vascularized fibular bone grafting in the treatment of congenital pseudarthrosis of the ulna was first reported by Allieu *et al*.⁽⁵⁾ in 1981. This technique probably works best in patients with a bony defect that is large and the radial head not dislocated. Reconstruction of the distal radioulnar and ulnocarpal joint using concomitant proximal fibular epiphyseal transfer should be considered in the skeletally immature patient with distal ulnar involvement.⁽²⁰⁾ Once the radial

head has been dislocated, other procedures should be considered because even if a union were achieved with vascularized graft, the elbow function would not be significantly improved and there would be a persistent growth discrepancy and progression problem at the elbow. A one-bone forearm procedure is a good alternative option once the radial head has been dislocated and when there is insufficient distal bone stock to hold a graft. This technique was described by Straub (1965)⁽²²⁾ and Lloyd-Roberts (1973),⁽²³⁾ in which the radius and the ulna were osteotomized at the same level, with the distal ulnar and proximal radial segments resected, and the distal radius and proximal ulna then fixed with an intramedullary pin. This is a short and easy procedure, which does not need surgical expertise in microvascular surgery, and has a good union rate that produces a stable forearm. However, its disadvantages are limitation of forearm rotation, and shortened forearm length.

Our patient had severe dysplastic proximal ulna with an absence of the middle and distal ulna. Also, the dislocated radial head was treated by gradually distracting the proximal radius downward to restore forearm length prior to the creation of a one bone forearm. This patient had a good functional and also cosmetic results. Our technique is a successful option in the treatment of congenital pseudarthrosis of the ulna with a large bony defect and dislocated radial head.

References

1. Moore JR. Delayed autogenous bone graft in the treatment of congenital pseudarthrosis. *J Bone Joint Surg Am* 1949;31:23-9.
2. Madsen ET. Congenital angulations and fractures of the extremities. *Acta Orthop Scand* 1956;25:242-80.
3. Cobb N. Neurofibromatosis and pseudarthrosis of the ulna. A case report. *J Bone Joint Surg Br* 1968; 50:146-9.
4. Shertzer JH, Bickel WH, Stubbins SG. Congenital pseudarthrosis of the ulna. Report of two cases. *Minn Med* 1969;52:1061-6.
5. Allieu Y, Gomis R, Yoshimura M, Dimeglio A, Bonnel F. Congenital pseudarthrosis of the forearm-two cases treated by free vascularized fibular graft. *J Hand Surg [Am]* 1981;6:475-81.
6. Ali MS, Hooper G. Congenital pseudarthrosis of the ulna due to neurofibromatosis. *J Bone Joint Surg Br* 1982;64:600-2.
7. Bayne LG. Congenital pseudarthrosis of the forearm. *Hand Clin* 1985;1:457-65.
8. Ostrowski DM, Eilert RE, Waldstein G. Congenital pseudarthrosis of the ulna: a report of two cases and a review of the literature. *J Pediatr Orthop* 1985;5:463-7.
9. Fabry G, Lammens J, Van Melkebeek J, Stuyck J. Treatment of congenital pseudarthrosis with the Ilizarov technique. *J Pediatr Orthop* 1988;8:67-70.
10. Bell DF. Congenital forearm pseudarthrosis: report of six cases and review of the literature. *J Pediatr Orthop* 1989;9:438-43.
11. Rajaratnam K, Shanker J, Varughese S. Pseudarthrosis of the ulnar and review of the literature. *J Pediatr Orthop* 1989;9:438-43.
12. Maffulli N, Fixsen JA. Pseudoarthrosis of the ulna in neurofibromatosis. A report of four cases. *Arch Orthop Trauma Surg* 1991;110:204-7.
13. Mathoulin C, Gilbert A, Azze RG. Congenital pseudarthrosis of the forearm: treatment of six cases with vascularized fibular graft and a review of the literature. *Microsurgery* 1993;14:252-9.
14. Masterson E, Earley MJ, Stephens MM. Congenital pseudarthrosis of the ulna treated by free vascularized fibular graft: a case report and review of methods of treatment. *J Hand Surg [Br]* 1993;18: 285-8.
15. Cheng JC, Hung LK, Bundoc RC. Congenital pseudarthrosis of the ulna. *J Hand Surg [Br]* 1994;19:238-43.
16. Craigen MA, Clarke NM. Familial congenital pseudarthrosis of the ulna. *J Hand Surg [Br]* 1995;20:331-2.

17. Witoonchart K, Uerpairojkit C, Leechavengvongs S, Thuvasethakul P. Congenital pseudarthrosis of the forearm treated by free vascularized fibular graft: a report of three cases and a review of the literature. J Hand Surg [Am]. 1999;24:1045-55.
18. Lee KS, Lee SH, Ha KH, Lee SJ. Congenital pseudarthrosis of the ulna treated by free vascularized fibular graft-a case report. Hand Surg 2000;5:61-7.
19. Suzuki O, Ishida O, Sunagawa T, Ichikawa M, Yasunaga Y, Ikuta Y, et al. Congenital pseudoarthrosis of the ulna treated with a free vascularized fibular graft. Plast Reconstr Surg 2005;15:115:1379-84.
20. Bae DS, Waters PM, Sampson CE. Use of free vascularized fibular graft for congenital ulnar pseudarthrosis: surgical decision making in the growing child. J Pediatr Orthop 2005;25:755-62.
21. Boero S, Catagni M, Donzelli O, Facchini R, Frediani PV. Congenital pseudarthrosis of the tibia associated with neurofibromatosis-1: treatment with Ilizarov's device. J Pediatr Orthop 1997;17:675-84.
22. Straub LR. Congenital Absence of the Ulna. Am J Surg. 1965 Mar;109:300-5.
23. Lloyd-Roberts GC. Treatment of defects of the ulna in children by establishing cross-union with the radius. J Bone Joint Surg Br 1973;55:327-30.

ภาวะข้อต่อลงตั้งแต่กำเนิดของกระดูกอัลน่า และการรักษาแบบรวมกัน เพื่อคงความยาวของแขนและสร้างให้เกิดกระดูกชิ้นเดียวของแขนส่วนล่าง: รายงานผู้ป่วย

ยุทธเสริฐ ศิริรุ่งเรืองสาร, พ.บ., อนุพงษ์ เลาหพูนรังษี, พ.บ., คณิตต์ สนั่นพานิช, พ.บ.

ภาควิชาออร์โทปิดิกส์ คณะแพทยศาสตร์ มหาวิทยาลัยเชียงใหม่

บทคัดย่อ ภาวะข้อต่อลงตั้งแต่กำเนิดเฉพาะกระดูกอัลน่าพบได้น้อย ซึ่งสาเหตุของภาวะเกิดข้อต่อลงตั้งนั้น ยังไม่ทราบแน่ชัด การรักษาผู้ป่วยที่มีภาวะดังกล่าวนี้เป็นสิ่งที่ท้าทายและยุ่งยาก โดยจุดมุ่งหมายในการรักษาก็เพื่อทำให้เกิดความมั่นคงของแขน ป้องกันการเกิดภาวะแขนสั้น การ विकฤรูป และทำให้การทำงานของมือดีขึ้น ผู้รายงานได้นำเสนอผู้ป่วยที่มีภาวะข้อต่อลงตั้งแต่กำเนิดเฉพาะกระดูกอัลน่าที่มีการเคลื่อนหลุดของหัวกระดูกเรเดียสรวมด้วย ซึ่งผู้ป่วยมีปัญหารื่องความไม่มั่นคงของข้อศอกร่วมกับแขนที่สั้นและโก่ง และให้การรักษาโดยการใส่เครื่องตรึงกระดูกภายนอกชนิด Ilizarov เพื่อดึงกระดูกเรเดียสลงทำให้ความยาวแขนเพิ่มขึ้น และสร้างให้เกิดกระดูกชิ้นเดียวในแขนข้างนั้น พบว่า 2 ปีหลังการรักษาผู้ป่วยสามารถใช้มือทำงานได้ดี มีข้อศอกที่มั่นคงและมีแขน 2 ข้างยาวเท่ากัน ซึ่งนับว่าเทคนิคการรักษาที่ใช้ในผู้ป่วยรายนี้นับเป็นทางเลือกที่ดี และให้ผลสำเร็จในการรักษาภาวะข้อต่อลงตั้งแต่กำเนิดของกระดูกอัลน่าที่มีการหายไปของกระดูกอย่างมาก และมีการเคลื่อนหลุดของหัวกระดูกเรเดียสรวมด้วย *เชียงใหม่เวชสาร 2549;45(3):133-138.*

คำสำคัญ: ภาวะข้อต่อลงตั้งแต่กำเนิด กระดูกอัลน่า กระดูกชิ้นเดียวของแขนส่วนล่าง