

ตัวอย่างการเขียน operative note การผ่าตัดแก้ตาเข (minimal requirement)

Procedure and findings : Bilateral medial rectus recession 5.0 mm.

OD:

- inferonasal fornix conjunctival incision was made just anterior to plica semilunaris.
- RMR was hooked, identified and sutured with Vicryl 6/0 S-14.
- RMR was disinserted and recessed 5.0 mm. from original insertion as figured.
- The conjunctiva was closed with Vicryl 6/0 2 stitches.

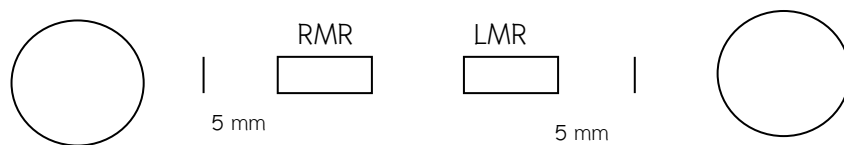
OS:

- similar procedure was done to LMR.

The bleeding was checked and cauterized throughout the procedure.

No intraoperative complication occurred.

EBL 0.2 ml.

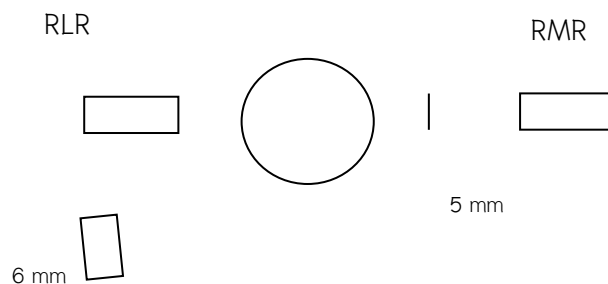


Signature.....

Procedure and findings : Medial rectus recession & Lateral rectus resection, OD

OD:

- inferonasal fornix conjunctival incision was made just anterior to plica semilunaris.
- RMR was hooked, identified and sutured with Vicryl 6/0 S-14.
- RMR was disinserted and recessed 5.0 mm. from original insertion as figured.
- The conjunctiva was closed with Vicryl 6/0 2 stitches.
- inferotemporal fornix conjunctival incision was made 8 mm from limbus.
- RLR was hooked, identified.
- intermuscular septa and check ligament were cut.
- Double armed Vicryl 6/0 was used to suture RLR at 6 mm.
- RLR was clamped and resected, then resutured to original insertion.
- The conjunctiva was closed 2 stitches with Vicryl 6/0.
- Bleeding was checked and cauterized as needed throughout the procedure.
- No intraoperative complication occurred.
- EBL 0.2 ml



Signature.....