Received: 9 September 2017 | Accepted: 30 October 2017

DOI: 10.1002/jcu.22566

CASE REPORT

WILEY

Intracranial fetus-in-fetu with numerous fully developed organs

Kuntharee Traisrisilp MD[1] | Kasemsri Srisupundit MD[1] | Songkiet Suwansirikul MD[2] | Thunya Norasetthada MD[3] | Shanika Kosarat MD[4] | Theera Tongsong MD[1]

[1]Department of Obstetrics and Gynecology, Faculty of Medicine, Chiang Mai University, Chiang Mai 50200, Thailand

[2]Department of Pathology, Faculty of Medicine, Chiang Mai University, Chiang Mai 50200, Thailand

[3]Department of Surgery, Faculty of Medicine, Chiang Mai University, Chiang Mai 50200, Thailand

[4]Department of Pediatrics, Faculty of Medicine, Chiang Mai University, Chiang Mai 50200, Thailand

Correspondence
Theera Tongsong, MD, Department of Obstetrics and Gynecology, Faculty of Medicine, Chiang Mai University, Chiang Mai 50200, Thailand.
Email: theera.t@cmu.ac.th

Funding information
No funding was secured for this study.

Abstract

Fetus in fetu (FIF) is an extremely rare anomaly featuring a monozygotic, diamniotic, parasitic twin, enclosed within its host twin. It is characterized by the presence of vertebrae and well-developed organs in a fetiform mass. Only 18 cases of intracranial FIF have been published. Of them, only five cases were prenatally detected. This study prenatally demonstrated triplet FIFs at 31 weeks within amniotic-like sac in the fetal skull, consisting of multiple well-defined organs. The FIF attached to the host twin via body stalk containing a single main feeding artery and vein, representing umbilical vessels. Surgical removal was performed at the age of two months. Pathological examination showed the triplet FIF, consisting of numerous well-developed organs (musculocutaneous-skeletal, nervous, respiratory, gastrointestinal systems etc.), with soft tissue/skin coverings, but no vertebral body was seen. Molecular genetic analysis revealed identical genetic mapping among the three FIFs and the host. This case provides strong evidence against Willis's hypothesis but supports Spencer's theory of abnormal twinning.

KEYWORDS

fetiform mass, fetiform teratoma, fetus-in-fetu, intracranial mass, prenatal diagnosis, ultrasound

1 | INTRODUCTION

Fetus-in-fetu (FIF) is a rare disorder featuring a monozygotic diamniotic, parasitic twin, attached by a vascular anastomosis to its host chorionic circulation. FIF usually presents as an amorphous mass of a fetus incorporated or enclosed into the body of its twin or host. It was first described by Meckel in 1800 and defined by Willis in 1953.[1] To date, <200 cases have been published. Most of them are localized in the retroperitoneal area of the host but can also be found in atypical sites, such as cranium, scrotum, mouth, and adrenal gland. Intracranial FIFs are very rare. To the best of our knowledge, only 17 cases have been reported in the literature. We report the prenatal diagnosis of an intracranial triplet FIF with advanced development and present the correlation with postnatal findings In addition, we review the published cases of intracranial FIF.

2 | CASE PRESENTATION

A 19-year-old primigravida was referred to our Center at 31 weeks of gestation for detailed anatomical scan. She was healthy, had no history of multifetal pregnancy in the family, and had not been exposed to any known teratogens or ovulatory-inducing drugs. Her marriage was not consanguineous. The current pregnancy course was uneventful. Anomaly screening at mid-pregnancy was unremarkable. At 31 weeks, ultrasound (US) examination on admission to our hospital revealed a female fetus with macrocephaly and a cyst containing fetiform mass in the brain (Figure 1 and Supporting Information, Videos 1 and 2). The biparietal diameter (10 cm) and head circumference (36 cm) were consistent with 40 weeks while the abdominal circumference (26 cm) and femur length (6 cm) were appropriate with gestational age. A complex fetiform mass ($9 \times 8 \times 7$ cm^3) occupied most of the cranium. Only a thin peripheral cortex of normal brain was identified. The mass contained solid and cystic components. Multiple well-formed long bones and bowel-like structure (sausage cysts) were visualized. Three contiguous fetiform masses were delineated in the same amniotic-like sac and connected to the host via a stalk containing a single set of main feeding vessels simulating umbilical vessels. Three feet or hand-like structures with skin/soft tissue coverings were well defined. One of the feet showed polydactyly. FIFs were the most likely diagnosis, with mature

 © 2017 Wiley Periodicals, Inc.

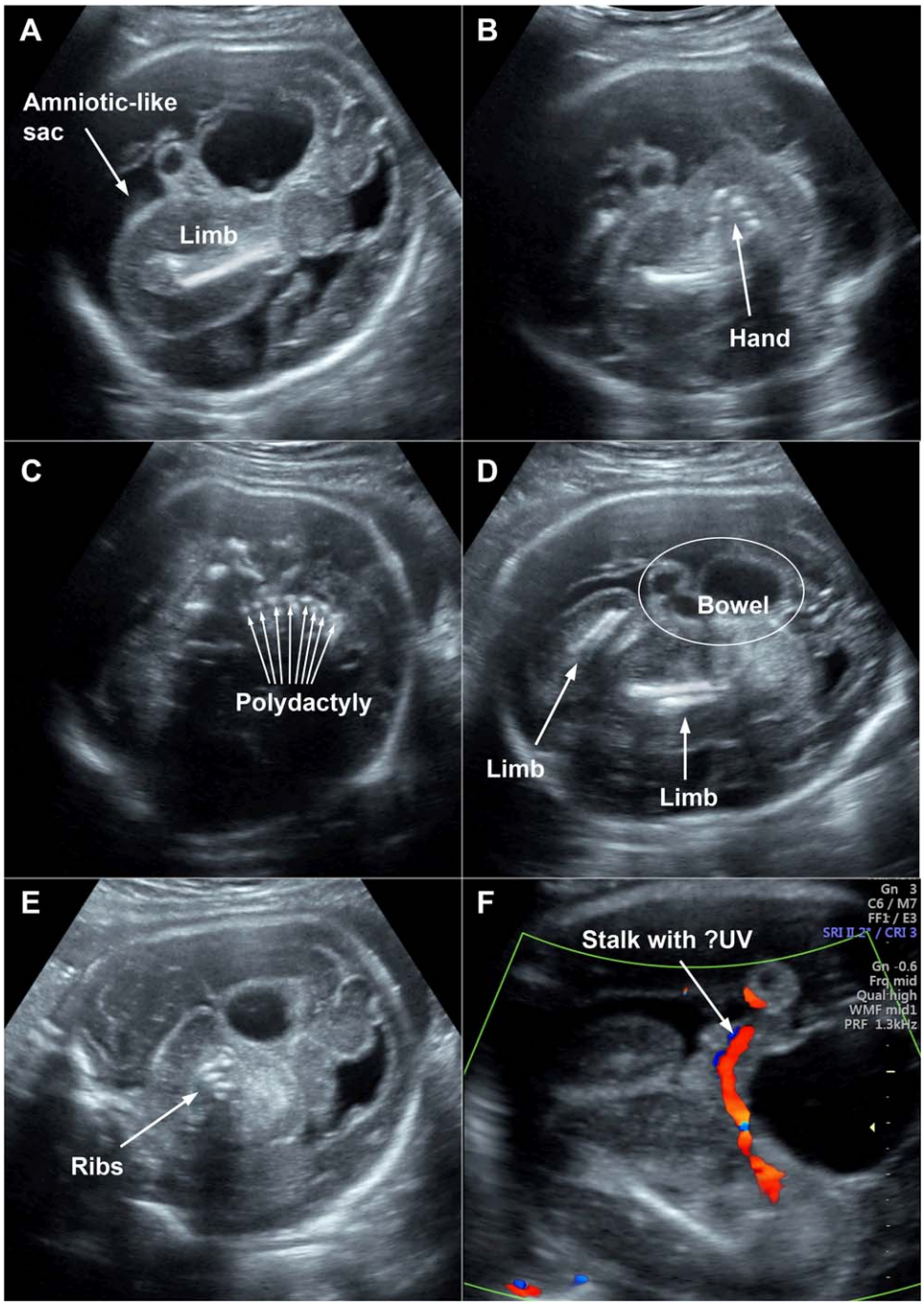

FIGURE 1 A-F, Sonograms of the fetal head at 31 weeks of gestation shows the fetiform complex mass. UV, umbilical vein

teratoma being the main differential diagnosis. Because of large intracranial mass with minimal residual brain, the prognosis was expected to be poor and prolongation of pregnancy with increase in fetal head size might preclude vaginal delivery, leading to unnecessary cesarean delivery of the nonsurviving baby. Accordingly, the parents chose termination of pregnancy with palliative care of the possibly surviving neonate. A female neonate was delivered vaginally weighing 1,950 gm with Apgar scores of 5 and 5 at 1 and 5 min, respectively. Grossly, the head was obviously enlarged with an occipitofrontal circumference of 37 cm (>90 centile for 31 weeks). Postnatal work-up confirmed the most likely diagnosis of FIF. Skull radiographs (Figure 2), CT scans, and MR images (Figure 3 and Supporting Information, Video 3) of the neonatal brain showed the mass consisting of cyst, skull, ribs, sacrum, pelvic bone, femur and foot, tibia, fibula, radius, ulna, fat contents, and heterogeneous enhancing soft tissue in the middle region of the brain. A large draining vein running from the mass into the superior sagittal sinus was also visualized. The mass caused hydrocephalus and displaced the brain parenchyma and cerebellum. The baby looked better than expected and survived with fair development with some gross motor defects. Two months after birth, the parents decided to have the baby undergo surgery. Fronto-parietal craniotomy was performed to remove the intracranial mass. The mass was covered by amniotic-

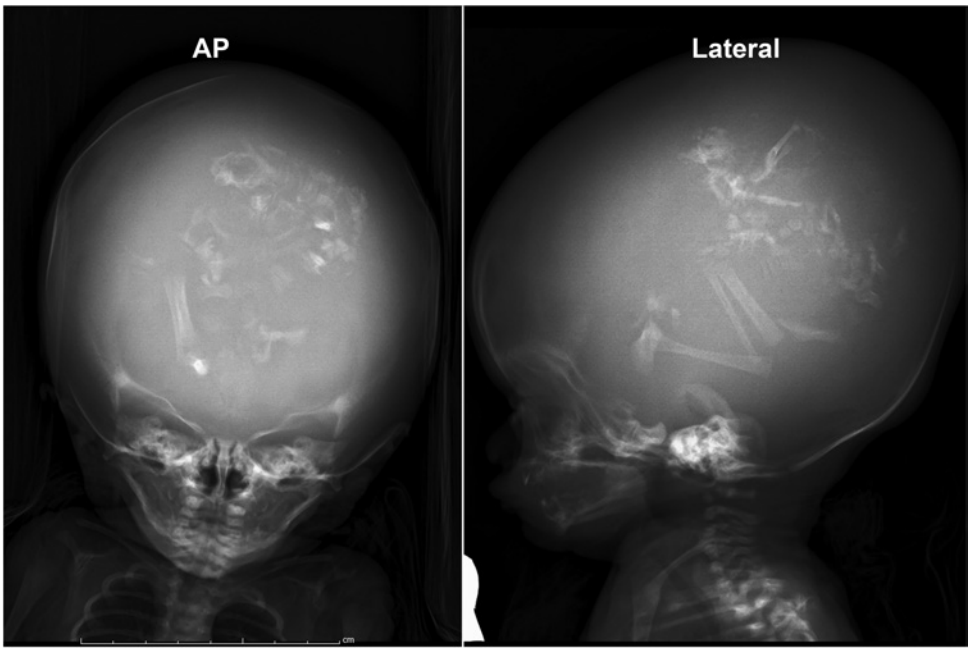

FIGURE 2 The neonatal skull radiographs show fetal bony structures in the twin host

like sac with fluid content. Three fetiform amorphous masses with skin coverage were enclosed in the sac (Figure 4). Main vessels were identified but the origin and destination of drainage were not well defined. The neonate had cardiac arrest during the operation and cardiopulmonary resuscitation was given but was not successful.

At pathological examination, one FIF showed numerous developed organs including both limbs with their appendages, brain tissue, thyroid tissue, salivary glands, upper and lower respiratory tract (bronchus, bronchiole and alveoli), gastrointestinal tract (stomach, small intestine, and colon), liver, adrenal gland, pancreas, long bones, pelvic bones, and

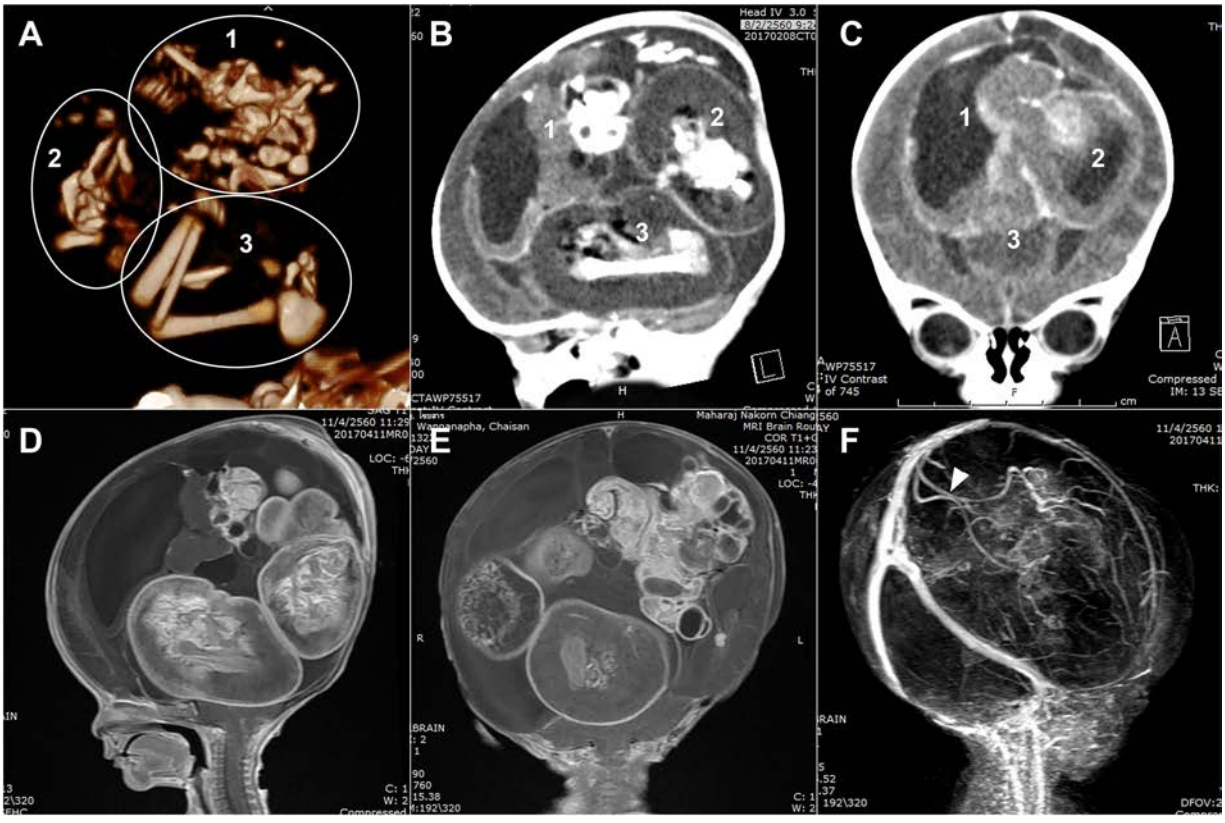

FIGURE 3 CT scans (A-C) and MR images (D-F) show 3 fetuses-in-fetu in the neonate's skull

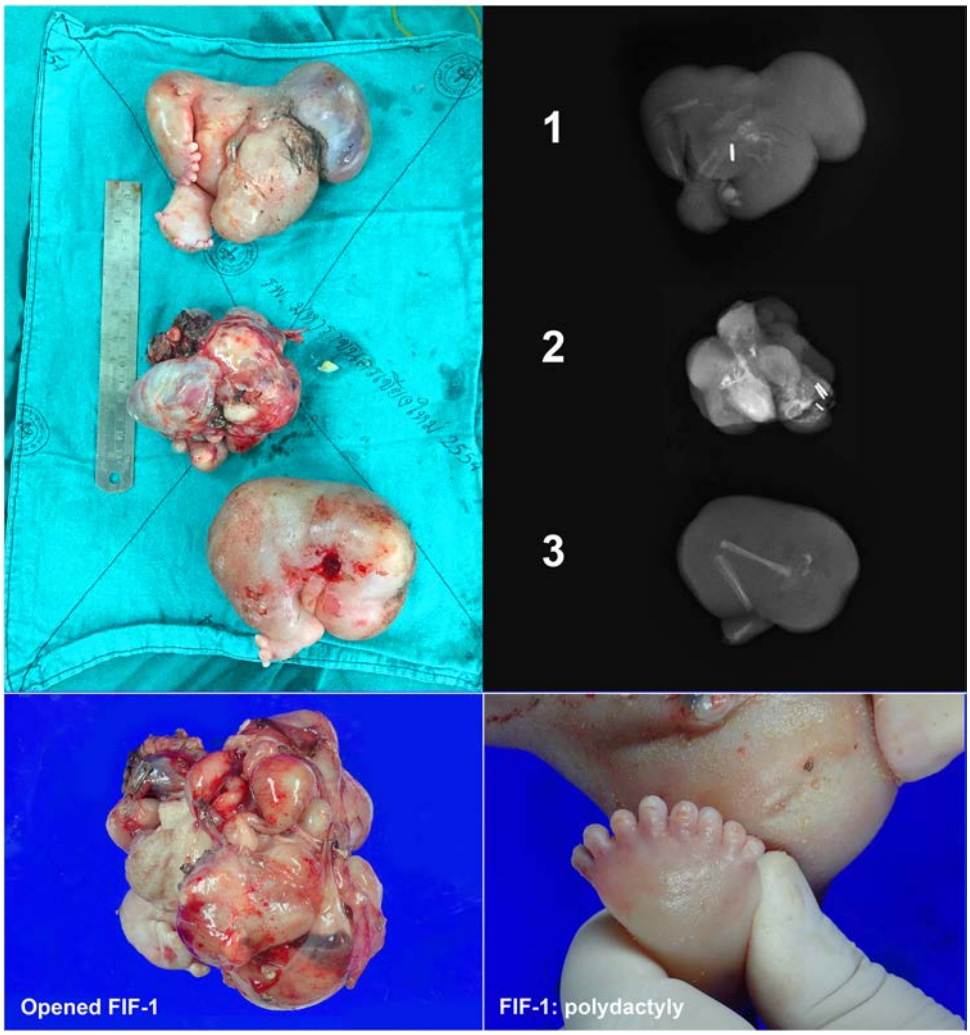

FIGURE 4 Gross specimens and specimen radiographs of the 3 fetuses-in-fetu removed from the host brain

ribs (Figure 5). The other two FIFs revealed similar findings with lesser degree of development.

Gene mappings of the host infant, FIF-1, FIF-2, and FIF-3 revealed exactly the same genes in all 16 examined locations (THO1, D3S1358, vWA, D21S11, TPOX, D7S820, D19S433, D5S818, D2S1338, D16S539, CSF1PO, D13S317, FGA, D18S51, D8S1179, and Amelogenin), confirming monozygotic twins.

The final diagnosis of FIF was based on the findings of (1) numerous well-developed fetal organs with relatively complete skin coverings, in amniotic-like sac, (2) a single set of main feeding vessels simulating umbilical vessels running through the stalk, and (3) the molecular genetic analysis indicating identical twinning.

3 | DISCUSSION

FIF is defined as the condition in which one fetus of monozygotic twins is incorporated into the body of its twin, comprising tissues from all three germ layers like a fetiform teratoma. FIFs are very rare, occurring once in every 500,000 births. It is often difficult to differentiate them from fetiform teratomas because of the same imaging and histological appearances. Mature cystic teratomas can be highly differentiated and may grossly resemble a fetus, hence the name of fetiform teratomas.[19] Patients with ovarian fetiform teratoma usually present between the ages of 7 and 65 years, with most cases diagnosed between 20 and 40 years.[20] The two entities may be distinguished by the following clinical clues[21,22]: (1) FIF is typically retroperitoneal and most commonly found in fetal life, infancy and early childhood, whereas fetiform teratomas are located in the ovaries of women of reproductive age in most cases. (2) An FIF typically contains a spine with differentiated limbs and organs around the central axis, whereas a fetiform teratoma usually contains no internal organs. (3) On the basis of zygosity, the two conditions have a different genetic pattern. An FIF has identical genetics to that of its host, whereas fetiform teratomas are homozygous.

In the extensive review of 87 cases by Hoeffel et al.,[23] 80% of FIFs were located in the retroperitoneal area but they could be found in other sites, including the head, sacrum, scrotum, mediastinum, lung, and kidneys.[24] The common organs found in the FIF were spine (91%) followed by limbs (85%), central nervous system (55.8%), gastrointestinal tract (45%), vessels (40%), and genitourinary tract (26.5%).[23] Most cases (88%) contained a single fetus[23] but there could be 2–5 FIFs.

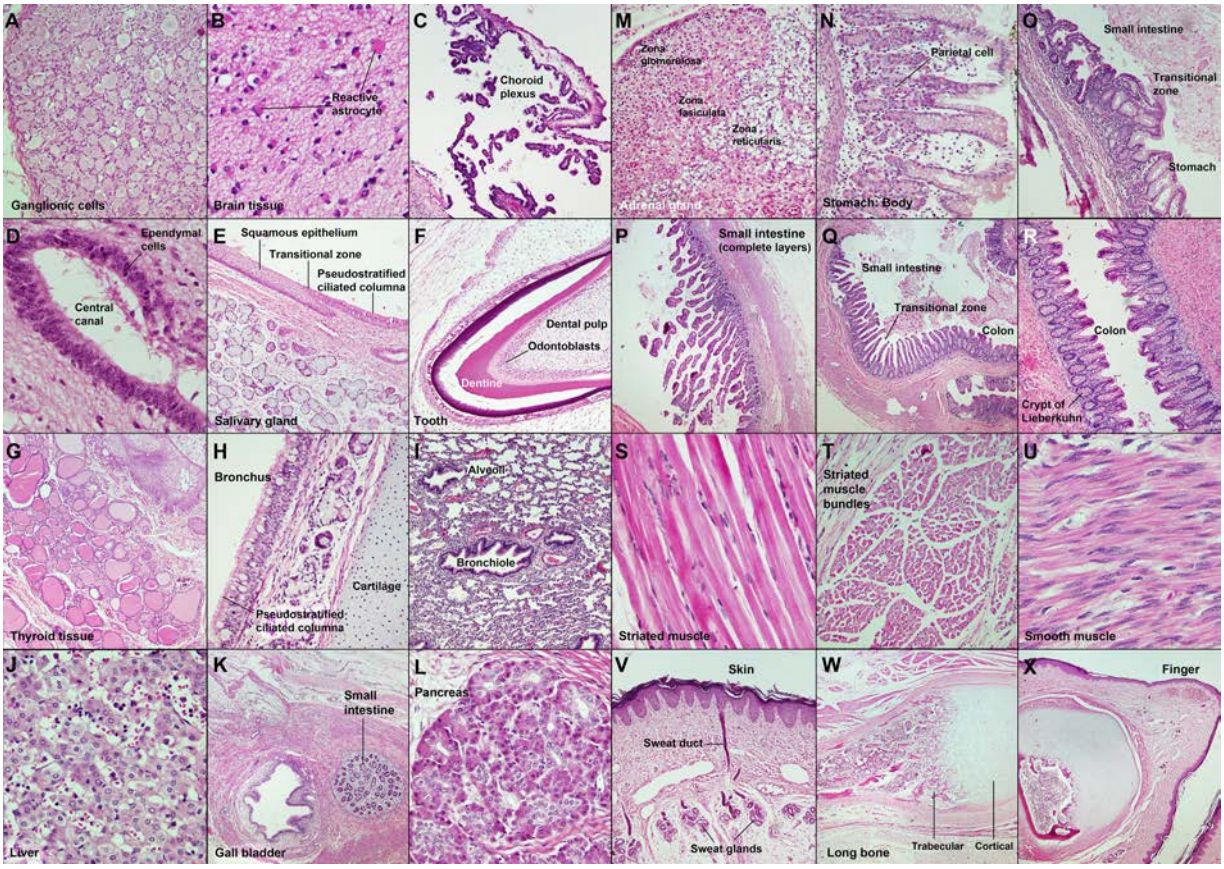

FIGURE 5 A-X, Photomicrographs of numerous fully developed organs present in fetus-in-fetu 1

To date, ~200 cases of FIF have been reported. Only 18 cases of intracranial FIF (including the case presented here) have been published (Table 1). In reviewing the literature, we have observed that multiple fetiform masses of FIF found at other sites were very rare but they were common with intracranial FIF (7/18; 39%), including a case of 21 rudimentary fetiform masses enclosed in the brain of a male stillborn.[4] While FIF has been reported with a male predominance (47:35),[23] our review shows that intracranial FIF has a female predominance. Whereas abdominal FIF has been reported to have favorable outcomes in most cases, intracranial FIF has fatal prognosis in most cases.

Intracranial FIFs can occur anywhere in the cranium with no predilection for a specific location. Finally, the diagnosis of intracranial FIF is rarely made prenatally (only in 5 of 18 cases in our review). It is possible that this lesion tends to develop late in the pregnancy and is therefore rarely detected at mid-pregnancy routine screening. This study underlines the importance of early prenatal diagnosis. In our case, if careful examination had been performed at mid-pregnancy when termination of pregnancy could be offered, the unnecessary hopeless surgery and the psychological trauma for the couple of carrying a pregnancy with lethal fetal lesions could have been avoided.

Prenatal diagnosis is now more readily being done by ultrasound and MRI. Typically, an abnormal mass or hydrocephalus on US screening is first detected and a brain tumor suspected, then more detailed US examination reveals fetal organ-like structures, especially vertebral bodies and well-defined limbs in the amnion-like sac. MRI may be used to illustrate more details.

It is controversial whether FIF is a distinct entity or a well-organized fetiform teratoma. Both may contain well-defined organs, even major body structures like vertebral column and limbs. FIF differs from fetiform teratoma in having vertebral column, bilateral symmetry, consisting of a complex fibrous membrane equivalent to chorioamnion,[12] whereas the teratoma usually occurs in the lower abdomen, ovaries, or sacral region and have tendency to malignant degeneration. According to Willis, the presence of a vertebral column is an important diagnostic criterion of FIF.[25] Nevertheless, its total absence does not exclude the diagnosis of FIF, possibly due to the invisibility on US of an underdeveloped and noncalcified vertebral column.[23]

According to diagnostic criteria for diagnosis of FIF proposed by Willis in 1935,[25] the presence of a vertebral column is necessary to differentiate it from a fetiform teratoma. Subsequently, Spencer et al.[26] proposed that in FIF, the fetiform structures should be enclosed within a distinct sac, partially or totally covered by well-developed skin, not necessarily containing a vertebral column. Furthermore, it should be connected to the host by a few large vessels located adjacent to the attachment, whereas a teratoma is less organized, and has broader attachment and multiple feeding vessels. These authors provided evidence that a teratoma and FIF are aberrations of monozygotic diamniotic twinning occurring at an early stage, before ventral fusion. A wide range of aberrations from external parasitic twin to FIF to mature

TABLE 1 Summary of consecutive cases of intracranial fetuses-in-fetu in literature (PubMed and Scopus search: June 2017)

Author (year)	Age	Sex	Location	Number	Vertebral column	Preoperative diagnosis	Outcomes
Kimmel (1950)[2]	1 day	F	Posterior cerebrum	5	+	-	Dead
Afshar (1982)[3]	6 weeks	F	Right and left lateral ventricles	1	-	-	Unknown
Povysilova (1983)[4]	1 day	M	Intracranial 21 minute rudimentary fetuses	21	-	-	Dead (Stillborn)
Yang (1992)[5]	2 months (Taiwan)	F	Occipital horn of left lateral ventricle	1	+	-	Dead (after surgery)
Hung (1993)[6]	2 months (Chinese)	F	Lateral ventricle and third ventricle	3	+	-	Unknown
Tsai (1993)[7]	2 months	F	Lateral ventricle and third ventricle	1	+	-	Dead
Naudin ten Cate (1995)[8]	-	F	Posterior cerebrum	6	+	-	Dead
Goldstein (1996)[9]	PND 24 weeks	F	Intracranial (occupied all head space)	1	-	-	Dead
Ianniruberto et al (2001)[10]	PND 18 weeks	ns	Posterior cranial fossa	1	+	+	Dead (TOP at 18 weeks)
Miura (2006)[11]	PND 21 weeks	M	Intracranial	1	+	-	Dead
Saito (2007)[12]	PND 19 weeks	M	Intracranial	6	+	-	Dead
Marnet (2008)[13]	1 day (hydrocephalusat 32 weeks)	ns	Third ventricle	1	-	PND (Ventricular mass)	Alive (at 15 months)
Kim (2008)[14]	4 months	M	Supratentorial	1	-	-	
Heuer (2008)[15]	6 years	F	Temporo-occipital	1	-	-	No operation
Huddle et al (2012)[16]	3 mo	F	Left lateral ventricle	2	+	-	Alive
Maryńczak (2014)[17]	1 day	M	Intracranial	1	-	PND (Intracranial mass) 31 weeks	Dead
Padwal (2016)[18]	7 months	F	Temporo-occipito-cervical	1	+	+	Alive
This case	PND 31 weeks	F	Most of the cranium	3	-	+; PND 31 weeks	Dead (postoperative complication)

Abbreviations: PND, prenatal diagnosis; TOP, termination of pregnancy; ns, not specified; M, male; F, female.

teratoma depend on the time of embryo-pathogenesis. Our case showed strong evidence in support of the diagnosis of FIF, including a well-defined embryologic spectrum within skin coverings, especially well-developed limbs with their appendages, brain, thyroid tissue, salivary glands, respiratory tract, gastrointestinal tract, liver, adrenal gland, pancreas, and a single set of large vessels representing umbilical vessels running through a stalk-like connecting area, and most importantly gene mappings indicating identical twinning. To the best of our knowledge, the case presented here is one of the most advanced cases with the greatest number of well-developed organs reported in the literature. It is to be noted that in spite of strong evidence supporting the diagnosis of FIF, no vertebral bodies could be identified in our case, supporting Spencer's theory rather than Willis's theory.

CONFLICT OF INTEREST

The authors have no conflicts of interest to disclose.

FINANCIAL DISCLOSURE

The authors have no financial relationships relevant to this article to disclose.

ORCID

Theera Tongsong MD http://orcid.org/0000-0002-3389-6478

REFERENCES

[1] Brand A, Alves MC, Saraiva C, et al. Fetus in fetu–diagnostic criteria and differential diagnosis–a case report and literature review. *J Pediatr Surg*. 2004;39(4):616.

[2] Kimmel DL, Moyer EK. A cerebral tumor containing five human fetuses; a case of fetus in fetu. *Anat Rec*. 1950;106(2):141.

[3] Afshar F, King TT, Berry CL. Intraventricular fetus-in-fetu. Case report. *J Neurosurg*. 1982;56(6):845.

[4] Povysilova V. Encranius with multiple rudimentary fetus in fetu in a premature boy. *Cesk Patol*. 1983;19:49.

[5] Yang ST, Leow SW. Intracranial fetus-in-fetu: CT diagnosis. *AJNR Am J Neuroradiol*. 1992;13(5):1326.

[6] Hung CF, Lam MS. Intracranial fetus in fetu: report of a case. *J Formos Med Assoc*. 1993;92(10):920.

[7] Tsai CH, Lin JS, Tsai FJ. Intraventricular fetus in fetu: report of one case. *Zhonghua Min Guo Xiao Er Ke Yi Xue Hui Za Zhi*. 1993;34(2):143.

[8] Naudin ten Cate L, Vermeij-Keers C, Smit DA, et al. Intracranial teratoma with multiple fetuses: pre- and post-natal appearance. *Hum Pathol*. 1995;26(7):804.

[9] Goldstein I, Jakobi P, Groisman G, Itskovitz-Eldor J. Intracranial fetus-in-fetu. *Am J Obstet Gynecol*. 1996;175(5):1389.

[10] Ianniruberto A, Rossi P, Ianniruberto M, Rella G, Ciminelli V. Sonographic prenatal diagnosis of intracranial fetus in fetu. *Ultrasound Obstet Gynecol*. 2001;18(1):67.

[11] Miura S, Miura K, Yamamoto T, et al. Origin and mechanisms of formation of fetus-in-fetu: two cases with genotype and methylation analyses. *Am J Med Genet A*. 2006;140(16):1737.

[12] Saito K, Katsumata Y, Hirabuki T, Kato K, Yamanaka M. Fetus-in-fetu: parasite or neoplasm? A study of two cases. *Fetal Diagn Ther*. 2007;22(5):383.

[13] Marnet D, Vinchon M, Kerdraon O, et al. Antenatal diagnosis of a third ventricular mass: fetus in fetu or teratoma?. *Childs Nerv Syst*. 2008;24(8):887.

[14] Kim JW, Park SH, Park SS, et al. Fetus-in-fetu in the cranium of a 4-month-old boy: histopathology and short tandem repeat polymorphism-based genotyping. Case report. *J Neurosurg Pediatr*. 2008;1(5):410.

[15] Heuer GG, Schwartz ES, Storm PB. Cranial fetus in fetu. Case illustration. *J Neurosurg Pediatr*. 2008;1(2):171.

[16] Huddle LN, Fuller C, Powell T, et al. Intraventricular twin fetuses in fetu. *J Neurosurg Pediatr*. 2012;9(1):17.

[17] Maryńczak L, Adamek D, Drabik G, et al. Fetus in fetu: a medical curiosity: considerations based upon an intracranially located case. *Childs Nerv Syst*. 2014;30(2):357.

[18] Padwal AD, Devi BI, Ramachandran S, Bhat DI, Shukla D, Ramu R. Occipitocervical fetus in fetu with extracalvarial extension: a case report. *Pediatr Neurosurg*. 2016;51(2):87.

[19] Scully RE. Classification of human ovarian tumors. *Environ Health Perspect*. 1987;73:15.

[20] Goldberg HR, Allen L, Kives S. Fetiform teratoma in the ovary of a 7-year-old girl: a case report. *J Pediatr Adolesc Gynecol*. 2017;30(2):256.

[21] Kuno N, Kadomatsu K, Nakamura M, et al. Mature ovarian cystic teratoma with a highly differentiated homunculus: a case report. *Birth Defects Res A Clin Mol Teratol*. 2004;70(1):40.

[22] Weiss JR, Burgess JR, Kaplan KJ. Fetiform teratoma (homunculus). *Arch Pathol Lab Med*. 2006;130(10):1552.

[23] Hoeffel CC, Nguyen KQ, Phan HT, et al. Fetus in fetu: a case report and literature review. *Pediatrics*. 2000;105(6):1335.

[24] Gilbert-Barness E, Opitz JM, Debich-Spicer D, Mueller T, Arnold SR, Quintero R. Fetus-in-fetu form of monozygotic twinning with retroperitoneal teratoma. *Am J Med Genet A*. 2003;120A(3):406.

[25] Willis RA. The structure of teratoma. *J Pathol Bacteriol*. 1935;40(1):36.

[26] Spencer R. Parasitic conjoined twins: external, internal (fetuses in fetu and teratomas), and detached (acardiacs). *Clin Anat*. 2001;14(6):428.

SUPPORTING INFORMATION

Additional Supporting Information may be found online in the supporting information tab for this article.

How to cite this article: Traisrisilp K, Srisupundit K, Suwansirikul S, Norasetthada T, Kosarat S, Tongsong T. Intracranial fetus-in-fetu with numerous fully developed organs. *J Clin Ultrasound*. 2018;46:487–493. https://doi.org/10.1002/jcu.22566